

## Original Article

## A Study on Prevalence, Morphology and Morphometric of *Gongylonema pulchrum* in Sheep Slaughtered in Sari, Northern Iran

Tahereh Mikaeili Galeh<sup>1,2</sup> Ph.D., Maryam Nakhaei<sup>2,3</sup> Ph.D., Ahmad Daryani<sup>2,4</sup> Ph.D., Shahabeddin Sarvi<sup>2,4</sup> Ph.D., Seyed Abdollah Hosseini<sup>2,4</sup> Ph.D., Shirzad Gholami<sup>2,4\*</sup> Ph.D.

<sup>1</sup> Department of Basic Medical Sciences, Khoy University of Medical Sciences, Khoy, Iran

<sup>2</sup> Toxoplasmosis Research Center, Mazandaran University of Medical Sciences, Sari, Iran

<sup>3</sup> Department of Parasitology, Faculty of Medicine, Mashhad University of Medical Sciences, Mashhad, Iran

<sup>4</sup> Department of Parasitology, Faculty of Medicine, Mazandaran University of Medical Sciences, Sari, Iran

### ABSTRACT

#### Article history

Received: 29 May 2022

Accepted: 29 Nov 2022

Available online: 15 Jun 2023

#### Keywords

*Gongylonema pulchrum*

Iran

Sheep

**Background and Aims:** The genus *Gongylonema* infects the upper digestive tract of birds, mammals, and humans. Livestock parasites, especially in the gastrointestinal tract, have caused irreparable damage, including death, reduced products, and economic losses. The present study aimed to reveal the prevalence and morphological and morphometric study of *Gongylonema* spp. isolated from the esophagus of slaughtered sheep in Sari, northern Iran.

**Materials and Methods:** Esophagi of 340 sheep were collected from Sari's industrial slaughterhouse during the summer and autumn of 2021 (summer= 115, autumn= 225). After longitudinal cutting, the surfaces of the esophageal mucosa were carefully checked under the light. The prevalence of infection was estimated, and the morphometric and morphological characteristics of the isolated worms were investigated using a calibrated light microscope and camera lucida.

**Results:** The prevalence of infection was 7.6% (26 isolates), which was estimated for summer and autumn 12 out of 115 (10.4%) and 14 out of 225 (6.2%), respectively. A comparison of morphological features of nematodes in this study with *Gongylonema* morphological criteria showed that all of them were *Gongylonema pulchrum*.

**Conclusions:** In the present study, a moderate gongylonemiasis infection was estimated in the sheep from Sari's industrial slaughterhouse. Morphological examination of the retrieved worms showed characteristic morphologies of *Gongylonema pulchrum*. To clarify the status of the infection, several morphological and molecular studies should be performed on different types of intermediate and final hosts of the parasite in different parts of the country.

## Introduction

*Gongylonema* is a nematode genus belonging to the superfamily Spiruroidea [1]. There are now about 50 species identified which parasitize mammals and birds [2]. So far, over 60 cases of human gongylonemiasis have been reported, with cases in Austria, Germany, Hungary, Japan, Spain, Thailand, France, the United States, China, New Zealand, and Iran [3-13]. This gullet worm has been found in Iranian cattle, sheep, buffalo, goats, wild boars, and donkeys [14]. According to studies conducted in Iran, the level of gongylonemiasis infection has been reported differently [14-19]. Sazmand et al., Naem et al., Eslami et al., Tavassoli et al. (2007), and Yousefi et al. reported the level of infection in sheep in different cities as 0%, 2%, 4.57%, 4.9%, and 8.5%, respectively [17-21]. In a study conducted by Halajian et al. on cattle slaughtered in Mazandaran province, the incidence of *G. pulchrum* was estimated at 25.4% [14]. Many researchers believe that the parasite does not cause much damage to the tissues of the esophageal wall, but Bleier et al. believe that this nematode can cause esophageal cancer [22]. The parasite's life cycle is indirect, and the mammalian hosts, as final hosts, become infected by ingesting infected arthropod intermediates and paratenic hosts or by consuming polluted water [20]. On ingestion by the final host, the third-stage larvae in the intermediate hosts are released and eventually migrate to the esophagus or oral cavity through the wall of the stomach or duodenum [23]. About 50 species of arthropods, such as beetles and cockroaches, are possible intermediate

hosts of *Gongylonema*. According to an analysis conducted in Iran, *Copris lunaris* may be a biological vector for the transfer of *Gongylonema* spp. to vertebrates [24]. Local inflammation of the oral mucosa, as well as occasional blood expectoration, pitchy stools, numbness of the tongue, pain in the chest and abdomen, vomiting, bloating, pharyngitis, and stomatitis, are the most common clinical symptoms of *Gongylonema pulchrum* (*G. pulchrum*) infection in humans. Clinical diagnosis of gongylonemiasis is difficult due to the rarity of the infection, transient symptoms, and the possibility of worms located in different parts of the oral cavity and esophagus [23]. Identification of *Gongylonema* spp. requires nematode removal and microscopic examination of the key morphologic features. Due to the difficulty of detecting *Gongylonema* eggs in the stools, it is difficult to diagnose the infection without removing the parasite [25]. Molecular diagnosis methods can confirm the diagnosis, and they are very helpful when morphological criteria are insufficient for identifying *Gongylonema* and differentiating species [26]. Investigating the prevalence and determination of parasite species in the host is important in controlling and preventing the disease. This research aimed to determine the prevalence rate of gongylonemiasis in sheep slaughtered in Sari's industrial slaughterhouse and examine morphological and morphometric characteristics of retrieved worms.

## Materials and Methods

Esophagi of 340 sheep were collected from Sari's industrial slaughterhouse during the summer and autumn of 2021 (summer = 115, autumn = 225). The collected samples were transported to the department of parasitology and mycology of Mazandaran University of Medical Sciences. First, the esophagi were cut longitudinally and thoroughly rinsed with water after removing food. Then mucosal surfaces were carefully checked under the light and with the naked eye. The worms embedded in zigzag tracks of the esophageal epithelium were retrieved, and the number of worms found in each esophagus was recorded. The isolated worms were relaxed in hot water and then fixed in 70% ethanol with 50% glycerin solution. The samples were placed in azocarmine and lactophenol solution for clearing and staining for several days. After estimating the prevalence, for examining morphological and morphometric characteristics of the genus *Gongylonema*, a calibrated light microscope and a camera lucida were used, and the required parts were photographed and measured. The body length, maximum body width, pharynx length, cervical lateral papillae, excretory pore, nerve ring, the total length of the esophagus, muscular esophagus length, glandular esophagus length, left spicule length, right spicule length, gubernaculum length, number of precloacal papillae, number of postcloacal papillae, vulva to end, tail length, egg length, and egg width were measured using a calibrated ocular micrometer (using an Anix

Software version 1.5 on the photos) at magnifications of 40× (25 µm per unit space), 100× (10 µm per unit space), and 400× (2.5 µm per unit space). The Mazandaran University of Medical Sciences Ethics Committee approved this cross-sectional study with the ethics ID code: IR.MAZUMS.REC.1398.656.

## Results

In this study, 340 esophagi of sheep were collected from Sari's industrial slaughterhouse during the summer and autumn of 2021, 26 (7.6%) of which were infected with *Gongylonema*. Of these, 32 male and 66 female worms were identified. There were one or more white to pink zigzag tracks in the mucosa of the infected esophagi, and the worms were embedded in the epithelium of the mucosa (Fig. 1). From 1 to 23 worms were recovered from the infected esophagi. Morphological examination of the worms showed characteristic morphologies of *G. pulchrum*. 12 out of 115 (10.4%) and 14 out of 225 (6.2%) esophagi were infected with *G. pulchrum* for the summer and autumn seasons, respectively. The seasonal variations of gongylonemiasis are shown in Table 1. The esophagi were more infected during summer (12, 10.4%) rather than autumn (14, 6.2%), but this difference was not statistically significant ( $p=0.17$ ). For both seasons, eight worms from each sex were selected, and their morphological characteristics were measured (Table 2). Due to the correct recovery of only one male worm from the esophagi collected in the summer, only its information was recorded for this sex.

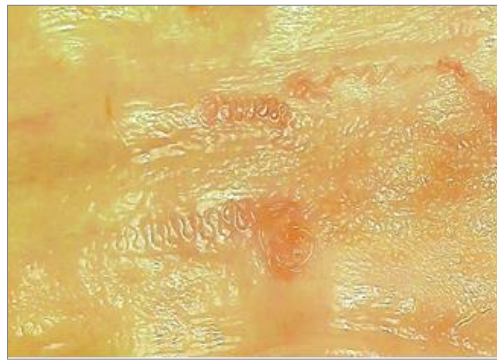


Fig 1. Zigzag tracks of *Gongylonema* in the esophageal epithelium

Table 1. Seasonal variations of gongylonemiasis in 340 esophagi of slaughtered sheep in Sari abattoir

Season	No. of Examined	No. of Infected (%)	No. of recovered worms (average)	No. of male worms (%)	No. of female worms (%)
Summer	115	12 (10.4%)	1-13 (3.7)	5/30 (16.7%)	25/30 (83.3%)
Autumn	225	14 (6.2%)	1-23 (5.5)	27/68 (39.7%)	41/68 (60.3%)
Total	340	26 (7.6%)	1-23 (4.7)	32/98 (32.6%)	66/98 (67.3%)

Table 2. Measurements of *Gongylonema pulchrum* collected from esophagi of slaughtered sheep in Sari abattoir

Season	Summer		Autumn	
	Male n= 1	Female n= 8	Male n= 8	Female n= 8
Sex/Number of worms examined				
Body length (mm)	47	84-130 (105.25 ± 10.6)	35-53 (47.5 ± 3.57)	88-133 (110.625 ± 10.1)
Maximum body width	307.25	344.5-485.25 (435.06 ± 33.5)	251-298.5 (278.19 ± 14.4)	384.75-538.5 (450.34 ± 32.75)
Pharynx length	39.375	38.925-49.6 (44.81 ± 2.6)	37.675-51.9 (42.51 ± 3.95)	41.65-56.8 (48.65 ± 2.9)
Esophagus length	5926.62 5	6964.5-10610.325 (8513 ± 845)	5037.125-6700.375 (6194.125 ± 340)	8145.7-10242.675 (8841.5 ± 482.5)
Muscular portion	538.325	773.075-1006.825 (863.975 ± 58.3)	537.625-799.25 (648.475 ± 56.2)	739.35-909.525 (823.613 ± 41.2)
Glandular portion	5388.3	6112-9603.5 (7355.05 ± 946)	4348-6162.75 (5545.65 ± 358)	7319.4-9333.15 (8017.98 ± 453)
Cervical lateral papillae*	156.88	143.68-172.13 (156.5375 ± 5.35)	111.53-158.48 (131.8438 ± 9.96)	122.6-171.83 (140.845 ± 10.3)
Nerve ring*	343	417.3-486.6 (458.55 ± 38.1)	335.6-441.8 (416.68 ± 50.7)	360.2-490.9 (431.68 ± 54.7)
Excretory pore*	540.7	593-768.3 (722.013 ± 40.9)	447.4-541.9 (514.48 ± 29.9)	621.4-804.8 (709.313 ± 34.8)
Left spicule (mm)	21.97		12.53-23.52 (19.56 ± 2.22)	
Right spicule	169.5		129.375-181.05 (157.91 ± 11)	
Gubernaculum	123.65		90.525-124.85 (104.81 ± 9.28)	
Number of precloacal papillae	5		5-6	
Number of postcloacal papillae	5		5	
Tail length	312.8	258.5-362.9 (347 ± 62.3)	282.3-322 (300.82 ± 10.3)	274.2-406.2 (307.85 ± 28.8)
Vulva to end		4055.25-6258.75 (5054.97 ± 627.79)		4115.5-7819.25 (5537.16 ± 862.5)
Egg length		52.725-60.25 (57.06 ± 1.49)		52.375-59.375 (56.19 ± 1.97)
Egg width		27.875-35.125 (31.9 ± 1.38)		31-34.4 (32.53 ± 0.91)

\* Distance from the anterior end. All measurements are in microns except body length and left spicule, which are in millimeters

The minimum body lengths of males and females were 35 and 84 mm. Males and females have maximum body lengths of 53 and 133 mm. The minimum size of the left and right spicules was 12.53 mm and 129  $\mu$ m. The maximum size of the left and right spicules was 23.52 mm and 181  $\mu$ m (Table 2). In our study, 126 out of 340 (37.1%) esophagi examined were infected with Sarcocystis cysts of different sizes. Sarcocystosis was also observed in 9 out of 26 (34.6%) esophagi infected with gongylonemiasis.

## Discussion

*G. pulchrum*, with minimal host specificity, infects a wide range of mammals, including domestic and wild species [14, 27]. Although it is primarily a parasite of ruminants, humans can get it accidentally [28]. There are numerous reports of human infections with *Gongylonema* from around the world [3-13]. In addition to infection of livestock and other animals, a human case of gongylonemiasis has been reported from Iran [13]. *Gongylonema* spp. has previously been reported from a dung beetle in Iran [24], but this parasite was not observed in a study with cockroaches in Sari [29]. In the present study, the prevalence of the parasite in the sheep was estimated at 7.6%, indicating a moderate infection level compared to the results of most studies conducted in different parts of Iran [14, 15-19]. Some studies in the country have reported high levels [14-16] and others low levels of infection in different hosts [17-19]. Studies carried out on sheep by Sazmand et al., Naem et al., Eslami et al., Tavassoli et al., and

Yousefi et al. in different cities reported the level of infection 0%, 2%, 4.57%, 4.9%, and 8.5%, respectively [17-21]. In a study conducted by Halajian et al. on cattle slaughtered in Mazandaran province, the incidence of *G. pulchrum* was estimated at 25.4% [14].

The reason for the variability of infection levels in the studies could be related to the sample size, industrial or native breeding of tested animals, sampling season, climatic conditions of the region, age of animals, etc. An insufficient sample size would cause an incorrect estimation of the infection load. Industrially bred livestock are usually less exposed to dung beetles and cockroaches that transmit the infection than native animals. Infection of livestock in warm seasons and hot and humid weather can be high due to suitable conditions for the growth, development, and survival of the infective larvae of this nematode and its intermediate hosts [30]. As studies have illustrated, the animal's age is one factor affecting the infection rate [14, 31]. Usually, the level of infection increases with the age of the sampled animals because of the increased risk of infection through frequent livestock grazing.

Although it is not easy to identify species of the genus *Gongylonema* using morphological characteristics, using the most stable taxonomic characters, such as total body length, left and right spicule lengths, etc., can be considered as having a specific value. By comparing the morphological characteristics of the isolated worms of the present study with

other studies [14, 31, 32], all of them were identified as *G. pulchrum*. The obligate intracellular protozoan *Sarcocystis* belongs to the Apicomplexan phylum, which has a prevalence of 74.40% in the ruminants of Iran [33]. In this study, the prevalence of *Sarcocystis* spp. in the esophagus of the studied animals was 37.1%, 7.1% of which had coinfection with *Gongylonema* spp. Despite its strengths, each study may also have weaknesses, and the following are the main limitations of our study: 1- The impossibility of slaughterhouse conditions to record the age and gender of the sampled animals, and as a result, not estimating the prevalence of parasite according to age and gender. 2- Lack of sufficient funds to conduct molecular studies. 3- The epidemic of Corona disease and the closure of universities and, subsequently, the impossibility of sampling in all seasons.

## Conclusions

The present study estimated a moderate level of gongylonemiasis infection in the sheep from

Sari's industrial slaughterhouse during the summer and autumn of 2021. Morphological examination of the retrieved worms showed characteristic morphologies of *G. pulchrum*. To clarify the status of the infection, many studies are needed in different parts of the country as well as invertebrate vectors and various animals, including domestic, wild, industrial, and native, especially in areas with no data. Most importantly, in order to definitively diagnose *Gongylonema* species, in addition to morphological features, molecular validation is required, and studies should be conducted in this regard. Environmental hygiene and optimal livestock care are essential to increase livestock products and reduce parasitic infections.

## Conflict of Interest

The authors declare that they have no competing interests.

## Acknowledgments

The authors thank the Toxoplasmosis Research Centre (TRC) of Mazandaran University of Medical Sciences.

## References

- [1]. Ramesh NAB, Naz S. Redescription of *Gongylonema neoplasticum* fibiger & ditlevsen, 1914 (Spirurida: Spiruroidea: Gongylo-nematidae) from house rat *Rattus rattus* (Rodentia: Muridae) from Hyderabad, Sindh, Pakistan. *Pak J Parasitol.* 2020; 70: 17-21.
- [2]. da Costa Cordeiro H, de Vasconcelos Melo FT, Giese EG, Santos JND. *Gongylonema* parasites of rodents: A key to species and new data on *Gongylonema neoplasticum*. *J Parasitol.* 2018; 104(1): 51-9.
- [3]. Rysavy B, Sebek Z, Tendra F. The finding of *Gongylonema pulchrum* Molin, 1857 (nematoda) in man. *Folia Parasitol (Praha).* 1969; 16(1): 66.
- [4]. Weber G, Mache K. Skin manifestations of *Gongylonema pulchrum*-first observation in Germany in humans. *Hautarzt.* 1973; 24: 286-88.
- [5]. Amaszta M, Hollo F, Miskolczi L, Strobl I. [The first case of human gongylonematosis in Hungary]. *Orv Hetil.* 1973; 114(37): 2237-238.
- [6]. Haruki K, Furuya H, Saito S, Kamiya S, Kagei N. *Gongylonema* infection in man: a first case of gongylonemosis in Japan. *Helminthologia.* 2005; 42(2): 63-6.



- [7]. Illescas-Gomez MP, Rodriguez Osorio M, Gomez Garcia V, Gomez Morales MA. Human Gongylonema infection in Spain. *Am J Trop Med Hyg.* 1988; 38(2): 363-65.
- [8]. Pasuralertsakul S, Yaicharoen R, Sripochang S. Spurious human infection with Gongylonema: nine cases reported from Thailand. *Ann Trop Med Parasitol.* 2008; 102(5): 455-57.
- [9]. Pesson B, Hersant C, Biehler JF, Abou-Bacar A, Brunet J, Pfaff AW, et al. First case of human gongylonemosis in France. *Parasite* 2013; 20: 5.
- [10]. Wilson ME, Lorente CA, Allen JE, Eberhard ML. Gongylonema infection of the mouth in a resident of Cambridge, Massachusetts. *Clin Infect Dis.* 2001; 32(9): 1378-380.
- [11]. Feng LC, Tung MS, Su SC. Two Chinese cases of Gongylonema infection; a morphological study of the parasite and clinical study of the cases. *Chin Med J.* 1955; 73(2): 149-62.
- [12]. Johnston TH. A note on the occurrence of the nematode Gongylonema pulchrum in man in New Zealand. *N Z Med J.* 1936; 35(187): 172-76.
- [13]. Mowlavi GH, Massoud J, Gutierrez Y. Human Gongylonema infection in Iran. *J Helminthol.* 2006; 80(4): 425-28.
- [14]. Halajian A, Eslami A, Salehi N, Ashrafi-Helan J, Sato H. Incidence and genetic characterization of Gongylonema pulchrum in cattle slaughtered in Mazandaran Province, northern Iran. *Iran J Parasitol.* 2010; 5(2): 10.
- [15]. Eslami A, Farsad-Hamdi S. Helminth parasites of wild boar, *Sus scrofa*, in Iran. *J Wildlife Dis.* 1992; 28(2): 316-18.
- [16]. Anwar M, Rak H, Gyorkos TW. The incidence of Gongylonema pulchrum from cattle in Tehran, Iran. *Vet Parasitol.* 1979; 5(2-3): 271-74.
- [17]. Eslami A, Ashrafi-helan J, Vahedi N. Study on the prevalence and pathology of Gongylonema pulchrum (Gullet worm) of sheep from Iran. *Glob Vet.* 2010; 5(1): 45-8.
- [18]. Tavassoli M, Nazari Manesh M, Tajik H. Study of Gongylonema contamination in Ruminants in Urmia slaughter house. *Vet Res Biol Prod.* 2007; 74(1): 195-97.
- [19]. Naem S, Gorgani T. Gastrointestinal parasitic infection of slaughtered sheep (Zel breed) in Fereidoonkenar city, Iran. *Vet Res Forum.* 2011; 2(4): 238-41.
- [20]. Sazmand A, Ehsani-Barahman S, Moradi H, Abedi M, Bahirae Z, Nourian A. Esophageal gongylonemosis in ruminants slaughtered in Hamedan and Babol, Iran. *J Zoonotic Dis.* 2020; 4(2): 56-63.
- [21]. Youssefi MR, Hoseini SM, Abohasani M, Omidzahir Sh, Gafarzade M. Recognition of type occurrence and pathology of Gongylonema infection in esophagus of sheep in Babol abattoir. *J Comp Pathol.* 2010; 7(3): 329-32.
- [22]. Bleier T, Hetzel U, Bauer C, Behlert O, Burkhardt E. Gongylonema pulchrum infection and esophageal squamous cell carcinoma in a vari (Lemur macaco variegata; Kehr 1792). *J Zoo Wild Med.* 2005; 36(2): 342-45.
- [23]. Xiaodan L, Zhensheng W, Ying H, Hongwei L, Jianqiu J, Peiru Z, et al. Gongylonema pulchrum infection in the human oral cavity: A case report and literature review. *Oral Surg Oral Med Oral Pathol Oral Radiol.* 2018; 125(3): 49-53.
- [24]. Mowlavi G, Mikaeili E, Mobedi I, Kia E, Masoomi L, Vatandoost H. A survey of dung beetles infected with larval nematodes with particular note on Copris lunaris beetles as a vector for Gongylonema sp. in Iran. *Korean J Parasitol.* 2009; 47(1): 13.
- [25]. Ayala MA, Yench MW. Gongylonema: a parasitic nematode of the oral cavity. *Arch Otolaryngol Head Neck Surg.* 2012; 138(11): 1082-1084.
- [26]. Gürel T, Şinasi U. Prevalence and molecular diagnosis of Gongylonema pulchrum in cattle and sheep in the Samsun region. *Ankara Univ Vet Fak Derg.* 2021; 68: 129-35.
- [27]. Kinsella JM, Robles MD, Preisser WC. A review of Gongylonema spp. (Nematoda: Gongylonematidae) in North American rodents with description of a new species from the cotton rat, Sigmodon hispidus (Mammalia: Cricetidae). *Zootaxa.* 2016; 4107(2): 277-84.
- [28]. Movassaghi A, Razmi G. Oesophageal and gastric gongylonemiasis in a donkey. *Iran J Vet Res.* 2008; 9(1): 84-6.
- [29]. Motevalli-Haghi SF, Shemshadian A, Nakhaei M, Faridnia R, Dehghan O, Shafaroudi MM, et al. First report of Lophomonas spp. in German cockroaches (Blattella germanica) trapped in hospitals, northern Iran. *J Parasit Dis.* 2021; 45(4): 937-43.
- [30]. Kheirandish R, Radfar MH, Sharifi H, Mohammadyari N, Alidadi S. Prevalence and pathology of Gongylonema pulchrum in cattle slaughtered in Rudsar, northern Iran. *Sci Parasitol.* 2013; 14(1): 37-42.
- [31]. Kudo N, Oyamada T, Ito K. Epizootiology of the gullet worm, Gongylonema pulchrum Molin, 1957, from cattle in Aomori Prefecture, Japan. *Kiseichugaku Zasshi.* 1992; 41(4): 266-73.
- [32]. Baylis H. On the species of Gongylonema (Nematoda) parasitic in ruminants. *J Comp Pathol Ther.* 1925; 38: 46-55.
- [33]. Anvari D, Narouei E, Hosseini M, Narouei MR, Daryani A, Shariatzadeh SA, et al. Sarcocystosis in ruminants of Iran, as neglected food-borne disease: A systematic review and meta-analysis. *Acta Parasitol.* 2020; 65(3): 555-68.